

Clitorolabial Reconstruction in Circumcised Females with Clitoral Inclusion Cyst

Yasir S. Jamal, FRCS(I), FICS and **Sabah S. Moshref**¹, FRSC(I)

*Department of Surgery, Division of Pediatric Surgery
and ¹Division of Plastic Surgery, Faculty of Medicine
King Abdulaziz University, Jeddah, Saudi Arabia*

ysmsj@yahoo.com

Abstract. The current practice of female circumcision in some communities, including some Islamic communities, is a form of genital mutilation. This results in structural distortion of the female external genitalia and defective sexuality, in addition to the associated immediate and late complication. Such practice should be condemned and the mutilated genitalia should be restored whenever feasible. 32 female patients who had Type I or II circumcision, complicated with clitoral inclusion cysts, were seen in the outpatient clinic over 12 years (January 1997 - December 2008) and were included in this study. All patients had excision of the clitoral cysts followed by clitorolabioplasty to restore their external genitalia. This report describes the detailed steps of our clitorolabial reconstruction, including the reconstruction of the clitoral hood, pointing out the importance of some steps on the cosmetic outcome. Patients with total clitoral shaft and hood excision were not candidate for such genital reconstruction and were not included in this study. This study presents an experience in female genital reconstruction of the mutilated circumcised female with reference to patients who developed clitoral inclusion cyst which act as tissue expander providing extra skin for better reconstruction.

Keywords: Female circumcision, Clitoroplasty labioplasty, Female genital reconstruction, clitoral inclusion cyst.

Correspondence & reprint request to: Prof. Yasir S. Jamal
P.O. Box 80215, Jeddah 21589, Saudi Arabia
Accepted for publication: 29 August 2009. Received: 23 May 2009.

Introduction

The current practice of female circumcision in some communities, including some Islamic communities, is a form of genital mutilation which results in structural distortion of the female external genitalia and defective sexuality. In addition to the associated immediate and late complication of the procedure itself, such as post circumcision bleeding which might be fetal or late development of the clitoral inclusion cyst, labial adhesions and recurrent infection^[1,2]. The current practice of female circumcision and female genital mutilation are categorized into 3 types, as suggested by Morgan & Steinem. Type I involves the removal of the prepuce and/or tip of the clitoris referred to as Sunna circumcision. Type II involves clitoridectomy and excision of part, or all of the labia minora. Type III involves removal of the prepuce, the clitoris and the labia minora, plus part of labia majora with suturing the edges (infibulations) referred to as Pharaonic or Sudanese circumcision^[3].

It is worth mentioning that currently practice female circumcision in Muslim community, from the severely mutilating Pharaonic (Type III) circumcision to the less mutilating Sunna (Type I) circumcision are neither related nor mentioned in Islamic literature or instructions in regard to female circumcision. Female circumcision practice was from time of the pharaoh in its extreme manner. However, Prophet Mohammed, “peace be upon him”, instructed the ladies who were doing the female circumcision not to cut extensively and to limit the cut to minimal, to allow proper exposure of the clitoris for better genital appearance with better self acceptance. He also mentioned that it is in this minimal manner more favored by the husband for better marital relationship. It is very clear from the Prophet’s instruction to perform partial hoodectomy^[4]. This hoodectomy or clitoral unhooding is currently considered in the aesthetic literature as cosmetic procedure of the female genitalia. With mentioning the same advantage in relation to improve self esteem and better sexual function^[5].

Therefore, currently practice female mutilating circumcision should not be allowed, and should be condemned. The victims of such practice should be helped by restoring their external genitalia by clitorolabioplasty with consequent improve sexual function

This study presents an experience in female genital reconstruction of the mutilated circumcised female with reference to patients who

developed clitoral inclusion cyst which act as tissue expander, providing extra skin for better reconstruction.

Patients and Methods

Thirty-two female patients who had Type I or II circumcision, complicated with development of clitoral cysts were seen in the outpatient clinic over 12 years (January 1997-December 2008) and were included in this study. The youngest was 1-year-old and the eldest was 16-years-old. 30 patients presented with non-infected sizable (2 cm or more) clitoral cysts (Fig. 1a & 2a). The remaining 2 were presented with small size infected discharging collapsed clitoral cysts. They were treated with the appropriate antibiotics and operated 8 weeks after clearance of the infection. 2 patients of all were referred as cases of ambiguous genitalia. Two other patients were seen with clitoral cyst that had complete foreskin excision and an extensive clitoral shaft resection; leaving no hood and no clitoral tissue to be utilized in the genital reconstruction. These patients were not candidates for such procedure and were not included in this study as they had clitoral cyst excision only.

The expanded skin, over developed clitoral inclusion cyst, preserved as a flap with broad caudal pedicle to be used for covering the terminal part of the clitoral stump to form neoglans clitoris and to line the clitoral hood internally.

This reconstructive procedure (The clitorolabioplasty including the reconstruction of the clitoral hood (Fig. 1 & 2) was performed as follow:

A curved incision was placed cranially over the clitoral cyst at its upper edge (Fig. 1b & 2b). The flap was dissected caudally over the cyst preserving broad base caudally (Fig. 1c & 2c). This caudally based flap was used for clitoral stump covering an inner lining of the hood of the foreskin.

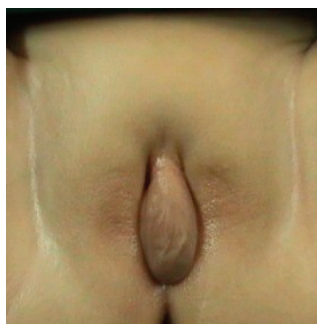

Fig. 1(a). Circumcised female with clitoral cyst.

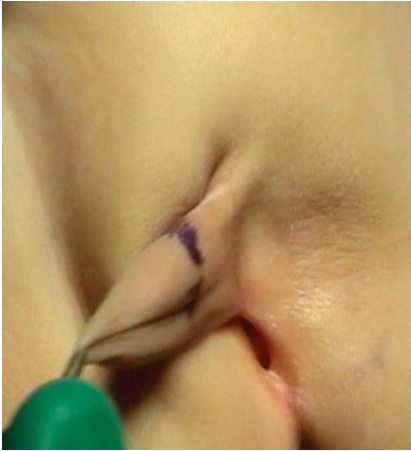

Fig. 1(b). Marking of the planned curved incision at the cranial end of the cyst to create a caudally based flap from the expanded skin over the clitoral cyst to wrap the neoglans clitoris and to line the clitoral hood.

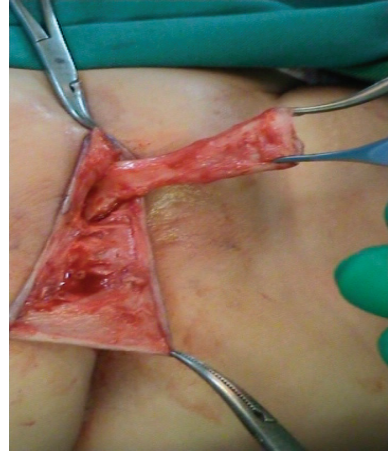

Fig. 1(c). The flap was created, the cyst and clitoral shaft dissected.

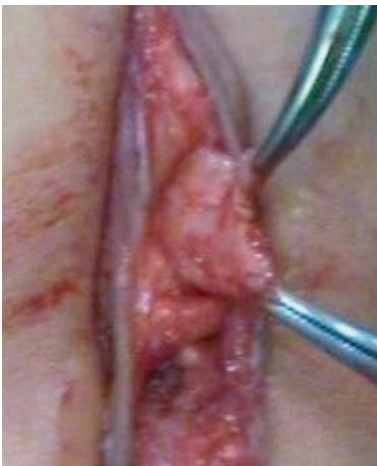

Fig. 1(d). Clitoral cyst was excised leaving clean clitoral stump. Release of the suspensory ligament.

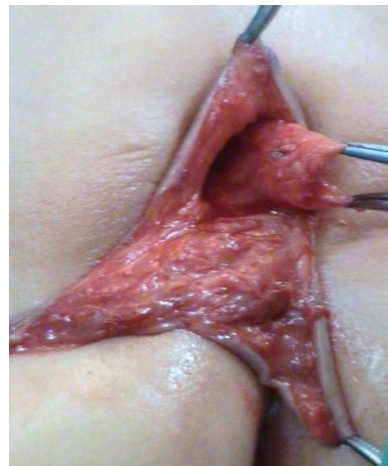


Fig. 1(e). Projecting the released clitoral shaft.

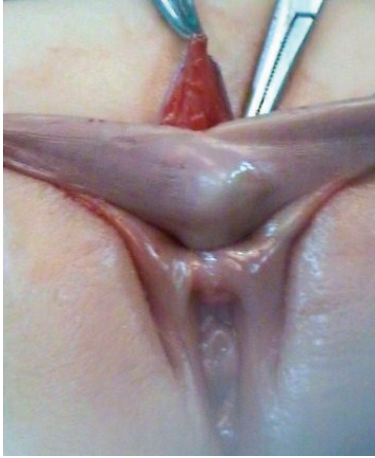

Fig. 1(f). Beginning of the clitoral wrapping of the neoglans clitoris caudally and on the sides.

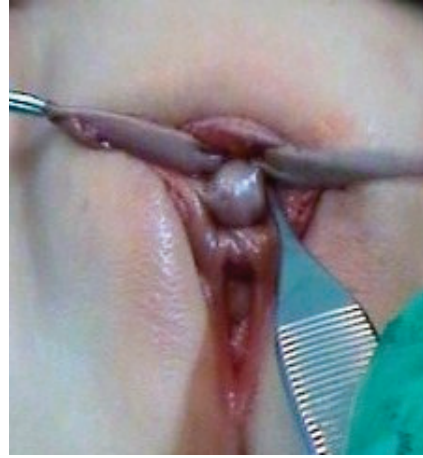

Fig. 1(g). Complete wrapping of neoglans clitoris.

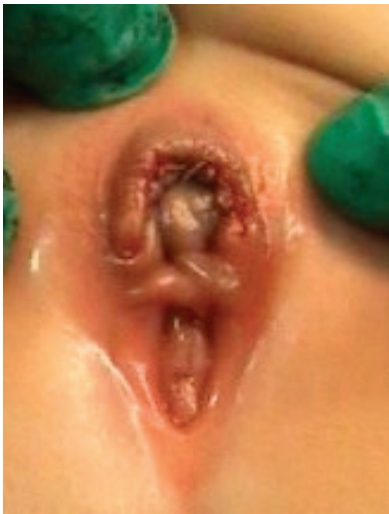

Fig. 1(h). Maintained anatomical relationship where the folds of both labia minora diverting caudally from the clitoris. The clitoral hood projecting over the labial folds and the clitoris.

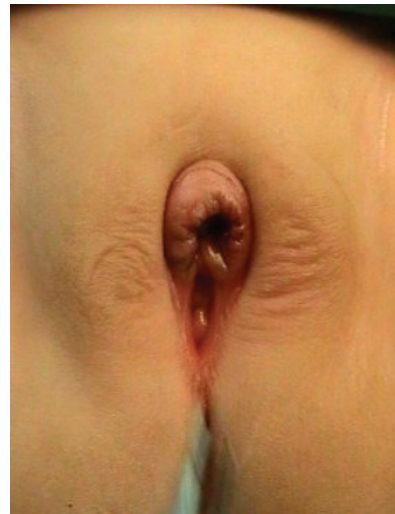


Fig. 1(i). Final appearance of the reconstructed external genitalia of previously circumcised female.

The clitoral cyst was excised by sharp dissection, leaving scar-free clean clitoral stump avoiding electrocautery to the outer surface of clitoral stump to protect the nerve ending. Thus, the corporeal bleeding can be controlled with diathermy needle (Fig. 1c, 1d, 2c & 2d).

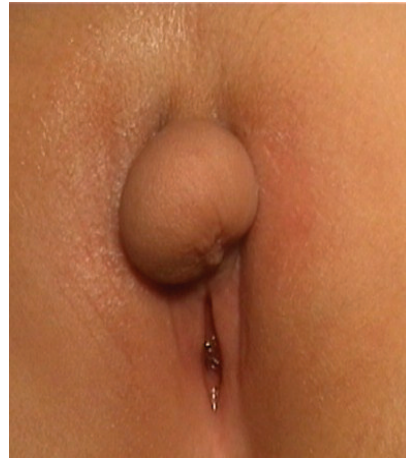


Fig. 2(a). Circumcised female with clitoral cyst.

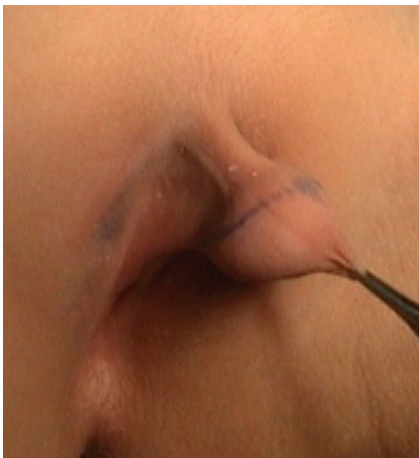

Fig. 2(b). Marking of the planned curved incision at the cranial end of the cyst to create a caudally based flap from the expanded skin over the clitoral cyst to wrap the neoglans clitoris and to line the clitoral hood.

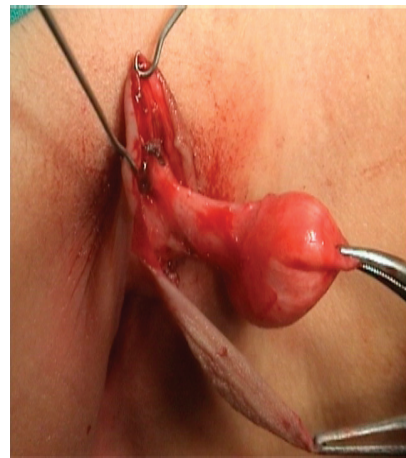

Fig. 2(c). The flap was created, the cyst and clitoral shaft dissected.

The remaining clitoral corporeal tissue made projected by releasing the suspensory ligament of the clitoris and reattaching it proximally to the pubic bone in about 2 cm projection manner using none absorbable stitch (3/0 Prolene) (Fig. 1e). Then, the ventral caudal skin

flap which was covering the cyst was used to wrap the projecting stump to simulate glans clitoridis. This skin wrapping of the clitoral stump was fixed with multiple fine absorbable interrupted stitches (Vicryl 5/0) all-around (Fig. 1f, 1g, 2f & 2g).

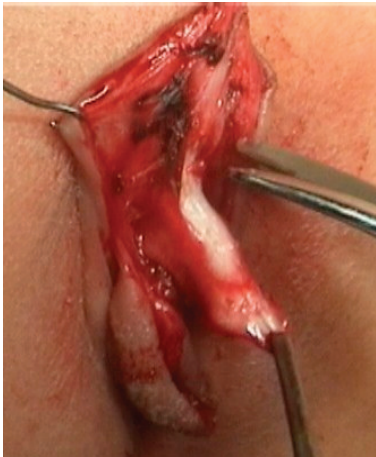

Fig. 2(d). Clitoral cyst excised leaving clean clitoral stump. Release of the suspensory ligament.

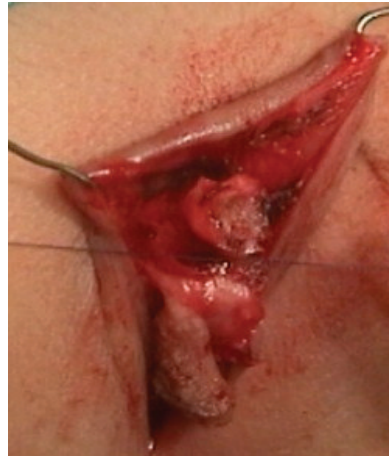


Fig. 2(e). Projecting the released clitoral shaft.

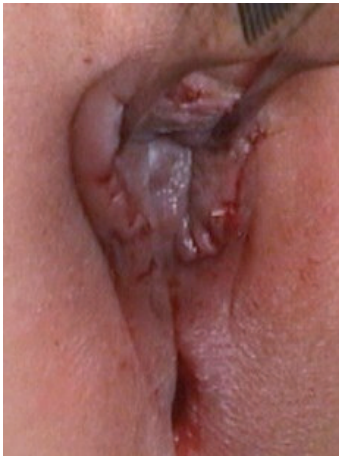

Fig. 2(f). Beginning of the clitoral wrapping of the neoglans clitoridis caudally and on the sides.

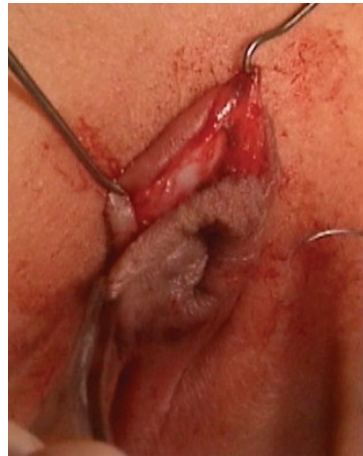

Fig. 2(g). Complete wrapping of neoglans clitoridis.

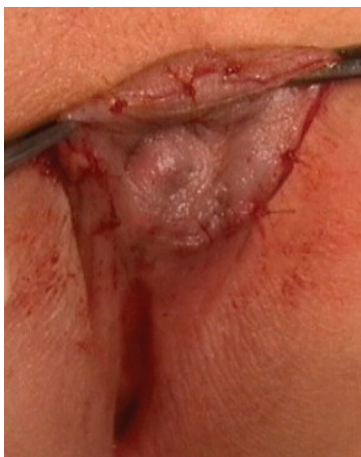

Fig. 2(h). The distal part of the flap lining, the inner aspect of the clitoral hood; maintained anatomical relationship where the folds of both labia minora diverting caudally from the clitoris. The clitoral hood projecting over the labial folds and the clitoris.

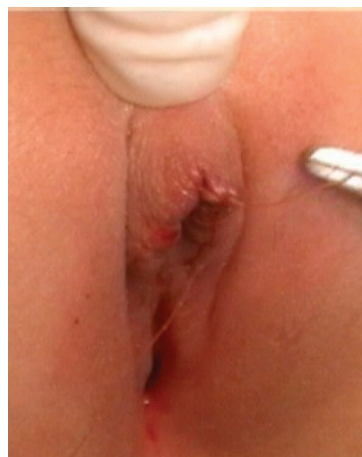

Fig. 2(i). Final appearance of the reconstructed external genitalia of previously circumcised female.

The remaining part of the flap was used to line the foreskin internally to create projecting hood over the clitoris giving natural appearance of the hood (Fig. 1h, 1i, 2h & 2i). To achieve this natural appearance of the foreskin, the lining flap should be sufficient to lay comfortably on the inner aspect. The free edge of the lining flap should be fixed with fine absorbable interrupted subcuticular stitches (Vicryl 5/0) on the inner aspect; particularly if this lining flap is short. The short lining and/or suturing edge to edge results in an inverted edge with thick rounded; none cosmetic clitoral hood (Fig. 3). When the skin flap is insufficient (small cyst or more skin needed to reconstruct labia minora in Type II circumcision), skin graft can be used for lining of the hood. As regard of the labioplasty, if the labia minora is not excised, as in Type I circumcision, it is important to maintain its relationship to the neoglans clitoris, and to divert caudally from neoclitoris. The fold of the clitoral hood will be projecting over both the glans clitoris and labia minora (Fig. 1h, 1i, 2h, & 2i). But, if labia minora excised as in Type II circumcision, the labia minora folds can be created from the local flaps at the base of the neoglans clitoris (Fig. 4), either at the same setting or in another stage to avoid necrosis of the flap covering the neoclitoris. Similarly, if patient

has post circumcision fusion of the labia, release of this adhesion should be delayed at least 6 weeks until the flap of the neoclitoris develops sufficient blood supply from the recipient area (Fig. 5).

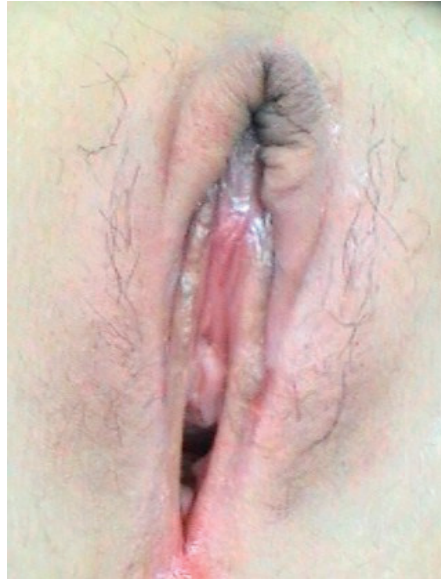

Fig. 3. Reconstructed external genitalia showing the inverted hood with broad non cosmetic edge due to insufficient skin for inner lining of the foreskin. This was corrected by releasing the flap and resuturing its edge to the inner aspect of the hood leaving the distal third which epithelialized from the flap.

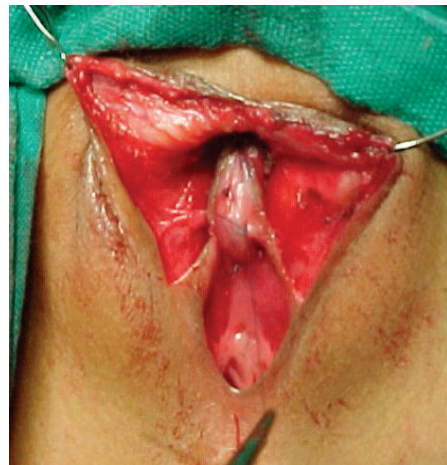
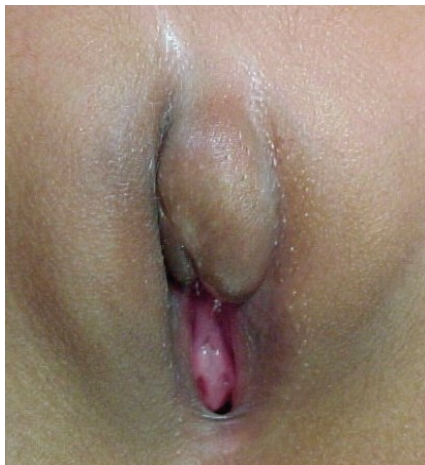

Fig. 4. Patient with complete excision of the labia minora which was reconstructed from the clitoral flap but there was shortage of the skin to line the inner aspect of the hood compensated with skin graft.

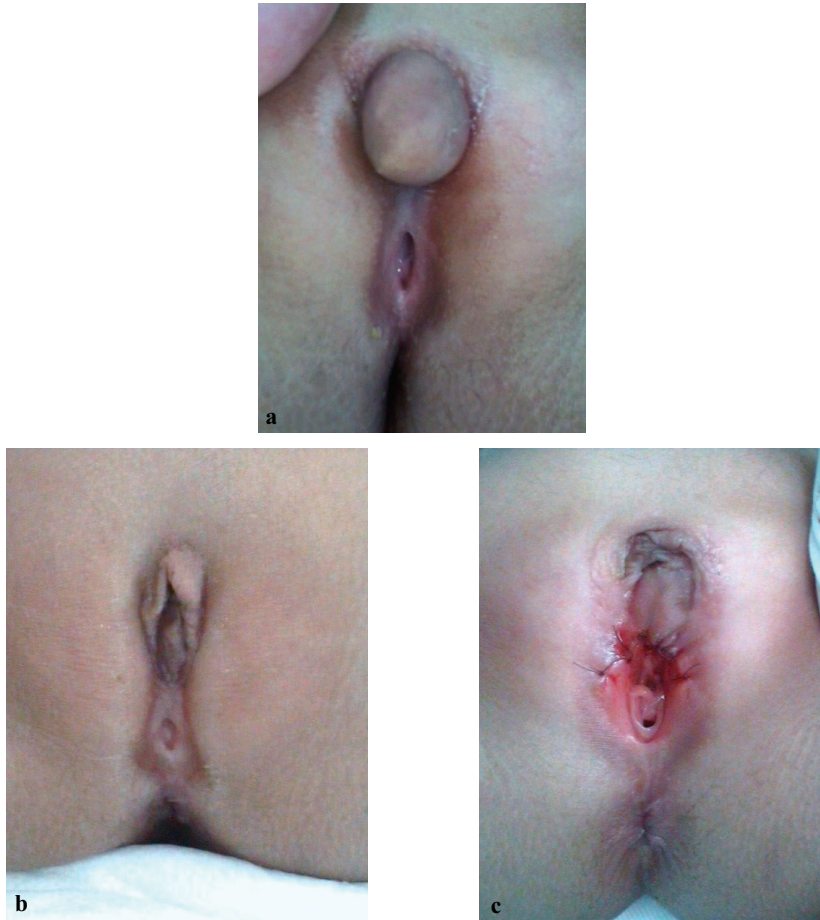


Fig. 5. Patient had the genital reconstruction in two operations due to the labial adhesions which was not possible to release it after the first operation to avoid compromising the blood supply to the base of the clitoral flap. (a). Before the first operation showing the labial adhesions at the base of the clitoral skin flap. (b). After the genital reconstruction with the non-released labial adhesions. (c). After the release of the labial adhesions in the second operation.

Our experience in reconstruction of the circumcised female without clitoral cyst, both pediatric and adult patients, none of them were included in this study

Results

All 32 patients had the excision of the clitoral cysts. 30 patients were having single cyst, but 2 were having 2 cysts attached to the clitoral

stump. In 30 patients, the skin flap was sufficient to wrap the neoglans clitoris and to line conformably the clitoral hood. But, in two patients the flap was not sufficient; one of them needed skin graft to line the hood. In the other patient, the flap was stitched to the inner aspect of the hood leaving the distal third which epithelialized from the flap. All patients had single operation, but two needed second operation to release the labial adhesions existing before the reconstruction, and were not released at the first operation to avoid compromising the blood supply to the base of the flap of the clitoris.

All patients were Type I or II circumcision. One of them had complete excision of the labia minora which needed reconstruction of the labia minora from local flap, and needed skin graft to line the hood (Fig. 4).

Pleased with the results of genital reconstruction of this group of patients who developed clitoral cyst, with the advantage of tissue expansion effect of the clitoral cyst, which provided sufficient skin for satisfactory reconstruction that resulted in near normal restoration of the female external genitalia, which met the parents' satisfaction.

Discussion

The current practice of female circumcision is a form of mutilation resulting in the disfigurement of the external genitalia of the female with the associated scarring, adhesions and inclusion cyst, leading to sexual dysfunction as reported by others. Inclusion clitoral cyst is a known post circumcision complication which might be treated by excision only or excision with immediate genital reconstruction^[1,2,6,7]. We strongly recommend the immediate genital reconstruction in the form clitorolabioplasty, including the reconstruction of the clitoral hood. Our experience showed very satisfactory results in bringing back the genitalia to feminine normality.

This work was not intended to evaluate the sexual function, but aimed at cosmetic genital reconstruction, and expecting an improved sexual function as a result of removal of the clitoral cyst with the scar tissue over the clitoral stump; and wrapping of the stump with healthy skin. In addition to the clitoplasty with the resulting clitoral projection, this improvement of the sexual dysfunction was indicated in the similar work which was done on adult patients^[6,7]. Also indicated in our

unreported experience with adult patients when reconstructed their genitalia, they reported more sexual satisfaction.

Therefore, in this pediatric age group, it was intended to present an experience with the technical steps for better cosmetic reconstruction of the external genitalia of the circumcised female. It empathizes the following steps in producing the satisfactory aesthetic result.

A. Proper mobilization, the remaining clitoral shaft will produce a projecting shaft compensating for the resected segment; wrapping of the terminal part of this projected shaft will produce neoglans clitoris.

B. Maintaining the hood-neoclitoris–labia minora anatomical relationship is of aesthetic importance; to bring back the normal appearance of the external genitalia, where the hood projects over the clitoris and the labia minora folds divert from the glans clitoris caudally.

C. Sufficient skin lining of the clitoral hood is essential to produce the natural projecting, non-inverted and thin edge clitoral hood.

D. The tissue expanding effect of the skin over the developed inclusion cyst participated in the better cosmetic outcome by providing extra skin sufficient to wrap the neoglans clitoris and to line the inner surface of the clitoral hood.

Conclusion

Our experience in genital reconstruction of the circumcised female with clitoral inclusion cyst, showed a very satisfactory cosmetic appearance and in restoring the female external genitalia to normality, which met the parents' satisfaction.

References

- [1] **World Health Organization.** Female genital mutilation. WHO. 2008; A61/11
- [2] **Wright J.** Female genital mutilation: an overview. *J Adv Nurs* 1996; **24**(2) : 251-259.
- [3] **Morgan R, Steinem G.** The international crime of genital mutilation. In: *Outrageous acts and Everyday Rebellions*. Steinem G. ed. Cape, London, 1983. 92-298
- [4] **Albar MA.** Female circumcision. In: *The Circumcision*. 1st ed. Makkah, Jeddah: Dar Almanarh for Publishing, 1994. 69-74.
- [5] **Goodman MP.** Female cosmetic genital surgery. *Obstet Gynecol* 2009; **113**(1): 154-159.
- [6] **Thabet SM, Thabet AS.** Defective sexuality and female circumcision: the cause and the possible management. *J Obstet Gynaecol Res* 2003; **29**(1): 12–19.
- [7] **Foldes P, Louis-Sylvestre C.** [Results of surgical clitoral repair after ritual circumcision. 453 cases] *Gynecol Obstet Fertile* 2006; **34**(12): 1137-1141.

إعادة تكوين الجهاز التناسلي لإناث مختنات يعانين من تكيس جلدي ما بعد الختان

ياسر صالح جمال، و صباح صالح مشرف^١

قسم الجراحة، وحدة جراحة الأطفال، و^١ وحدة جراحة التجميل، كلية الطب،
جامعة الملك عبدالعزيز، جدة - المملكة العربية السعودية

المستخلص. تعتبر الممارسة الحالية لختان الإناث في بعض المجتمعات نوع من التشويه والمثلة للجهاز التناسلي للإناث والذي يؤدي إلى القصور الجنسي، بالإضافة للمضاعفات الفورية والمتأخرة لعملية الختان، وهذه الممارسة يجب شجبها ويجدر مساعدة ضحايا هذا التشويه بإصلاح أجهزتهم التناسلية متى ما كان ممكناً. على مدى ١٢ عاماً تم اختيار ٣٢ أنثى ممن حضرن لعلاج تكيس جلدي بالبطر، بعد أن خضعن لختان الإناث من النوع الأول أو الثاني، وقد تم استئصال التكيس تبعه إصلاح للجهاز التناسلي للوضع الأنثوي الطبيعي. وقد أوضحنا تفاصيل العمل الجراحي مؤكداً أهم الخطوات للوصول إلى نتائج تجميلية مرضية في إصلاح الجهاز التناسلي، وقد تم استبعاد الحالات الغير مناسبة لهذه العملية، والتي تم فيها استئصال كامل البطر والغلفة في عملية الختان. وفي هذه الدراسة نقدم خبرتنا في عملية الإصلاح التجميلي للجهاز الأنثوي لمجموعة من البنات واللاتي تم ختانهن وحدث لهن بعده تكيس جلدي بالبطر.